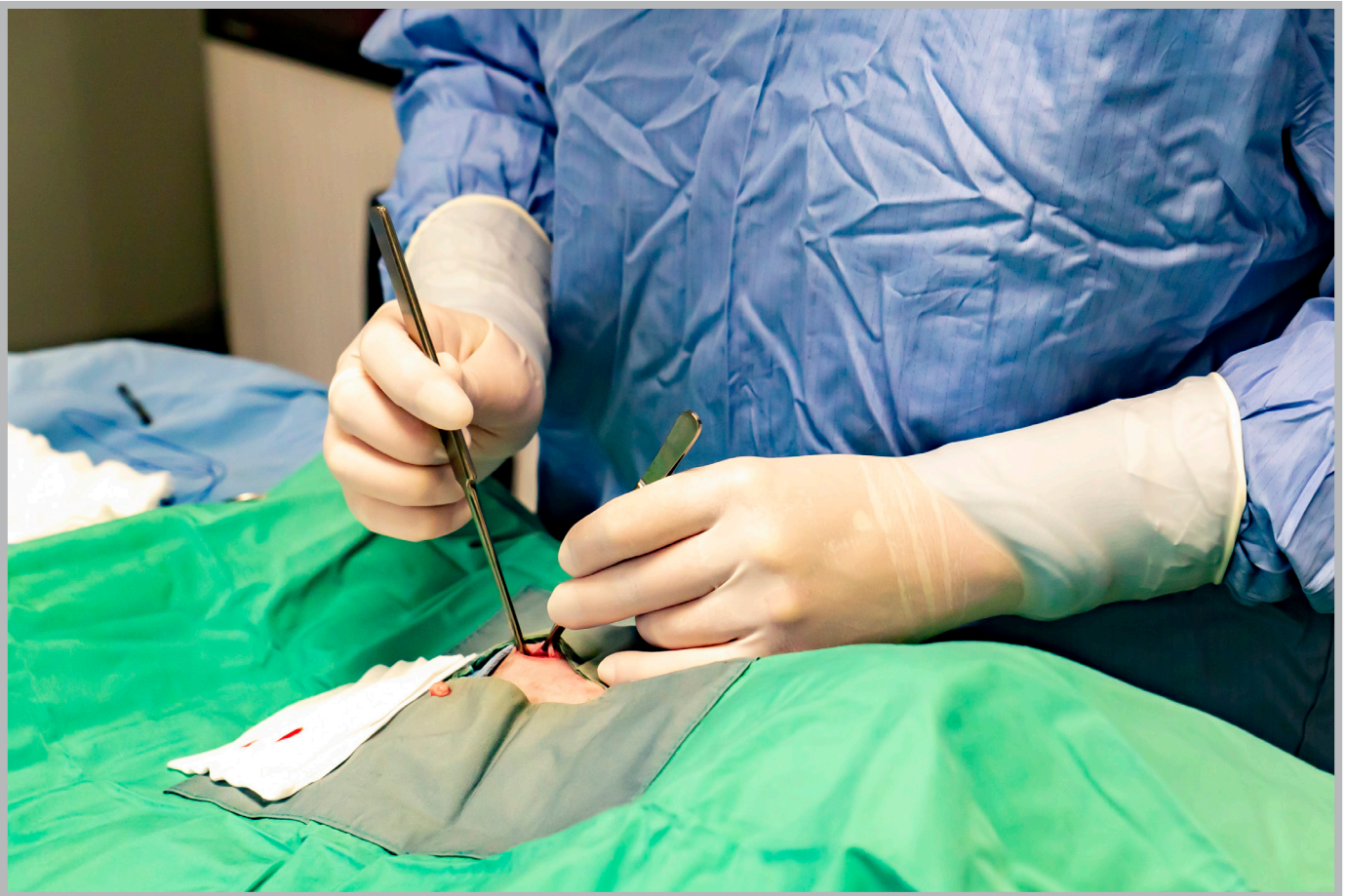


# High-Quality, High-Volume Spay/Neuter Surgical Techniques



**This “dry lab” manual was created to practically demonstrate efficient high-quality, high-volume spay/neuter techniques in a straightforward instructional format.**

Contributors: Brenda Griffin, DVM, MS, DACVIM; Karla Brestle, DVM; Mark Bohling, DVM, PhD, DACVS; Philip Bushby, DVM, MS, ACVS; Brian Digangi, DVM, MS, DABVP

## Table of Contents

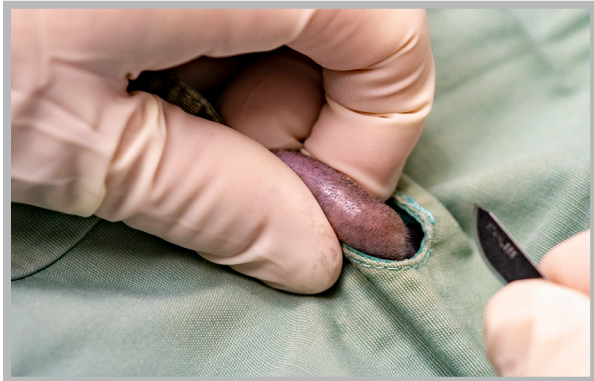

Chapter 1: <b>Approach for Scrotal Puppies</b> .....	<b>3</b>
Chapter 2: <b>Cord Tie</b> .....	<b>4</b>
Chapter 3: <b>Figure 8 Knot</b> .....	<b>6</b>
Chapter 4: <b>Feline Ovarian Pedicle Tie (Methods 1 &amp; 2)</b> .....	<b>9</b>
Chapter 5: <b>Strangle Knot</b> .....	<b>15</b>
Chapter 6: <b>Closure of the Rectus Sheath</b> .....	<b>18</b>
Chapter 7: <b>Scoring Tattoo</b> .....	<b>19</b>
Chapter 8: <b>Ear-tipping</b> .....	<b>20</b>

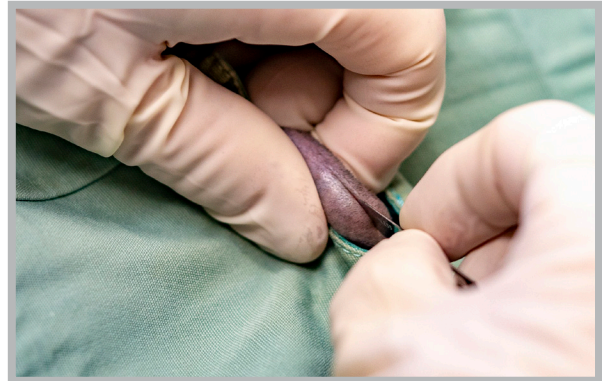
## Chapter 1: Approach for Scrotal Puppies

CLICK FOR MORE  
RESOURCES →

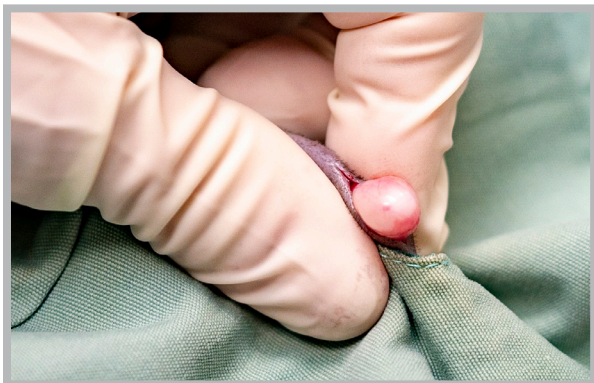
**Surgical Field:** Note the entire scrotum has been clipped and prepped for surgery.



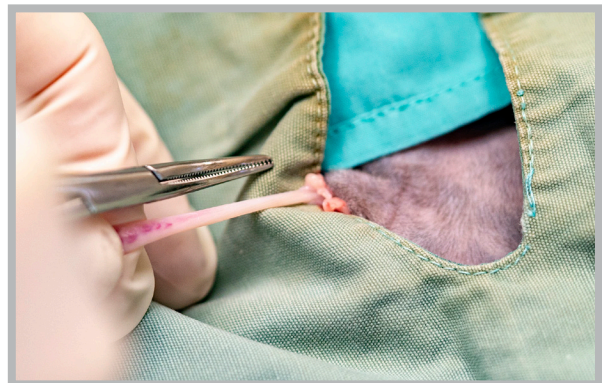
**1.** The surgeon grasps one testicle, positioning it such that the median raphe is elevated and exposed.



**2.** The incision is made on the median raphe. Both testicles will ultimately be removed through this same incision centrally located in the scrotum. This approach may be used in both pediatric puppy and feline castrations.



**3.** The testicle is exteriorized using gentle traction.



**4.** The cord is stripped of any excess tissue or fat. Open or closed technique may be used according to surgeon's preference.

A **cord tie** (see Chapter 2) or **figure 8 knot** (see Chapter 3) is used to ligate the spermatic cord according to surgeon's preference. For puppies, the general rule of thumb for determining if the cord can be ligated using one of these techniques is as follows: If the scrotum is not pendulous and the testicular size is no larger than that of a mature tomcat, then these techniques are appropriate. For larger testicles, suture is recommended for ligation. The procedure is repeated for the second testicle and the wound is left open to heal by second intention.

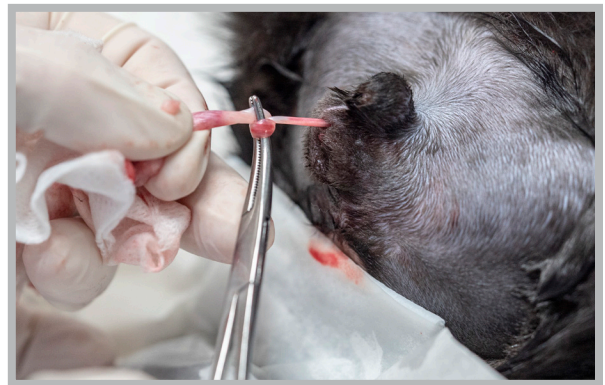
## Chapter 2: Cord Tie

CLICK FOR MORE  
RESOURCES →

A **cord tie** is an **auto-ligation technique** performed with a mosquito hemostat on the spermatic cord.

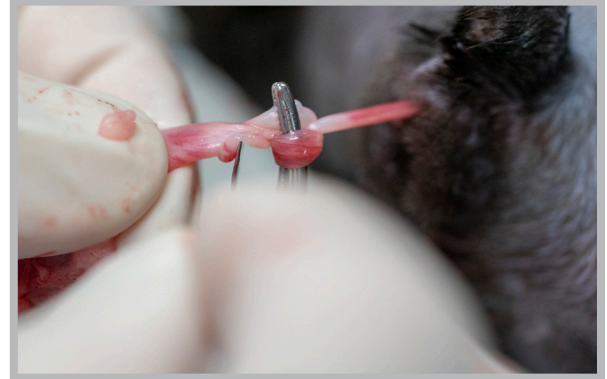

1. Once the cord has been isolated, the tip of the hemostat is passed under (ventrally) and around the cord.

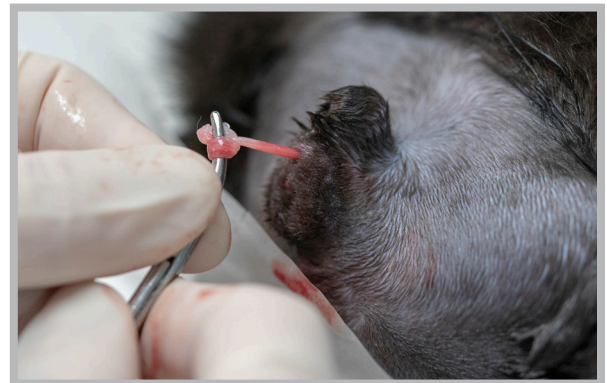


2. The jaws of the hemostat are then opened as the distal end of the cord (by the testicle) is advanced and around and up into them and clamped.

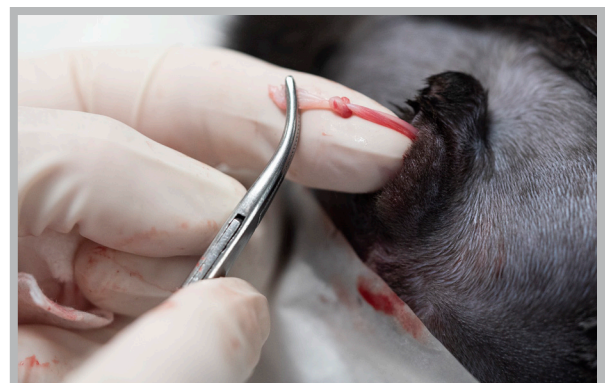

## Cord Tie (cont.)



3. Next, the cord is divided between the clamp and testicle (close to the clamp) using a scalpel blade or scissors.



4. Following removal of the testicle, the surgeon pushes the knot off of the tip of the hemostats.



5. The knot is tightened to ensure its security as the surgeon applies gentle proximal pressure to it. If necessary, excess cord may be trimmed but it is important to leave approximately 5 mm distal to the knot to ensure that it does not unravel. Inspect for bleeding before releasing.


## Chapter 3:

# Figure 8 Knot


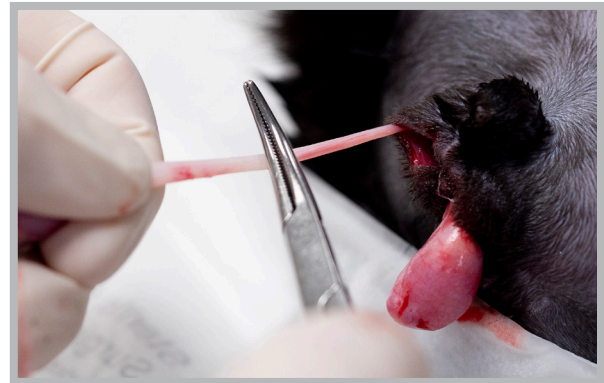
CLICK FOR MORE RESOURCES →

The **figure 8 knot** is a modification of the more common cord tie knot.

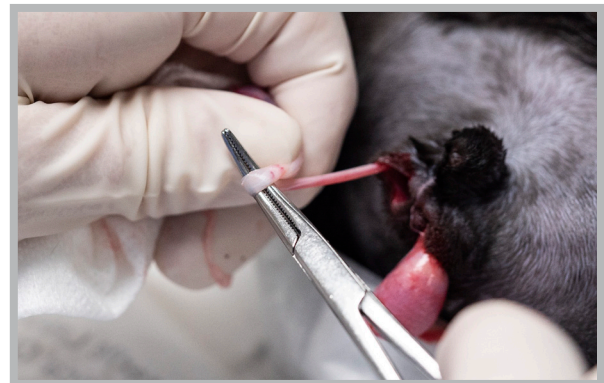
- The additional pass through the knot increases friction within the knot; this leads to increased security against untying when the knot is used for the cord tie for feline or pediatric puppy castration.
- The technique for tying the figure 8 knot using the hemostat requires only one simple modification to the cord tie: The surgeon holds the testis in the non-dominant hand and wraps the spermatic cord around the hemostat once, then proceeds to perform the cord tie as usual.



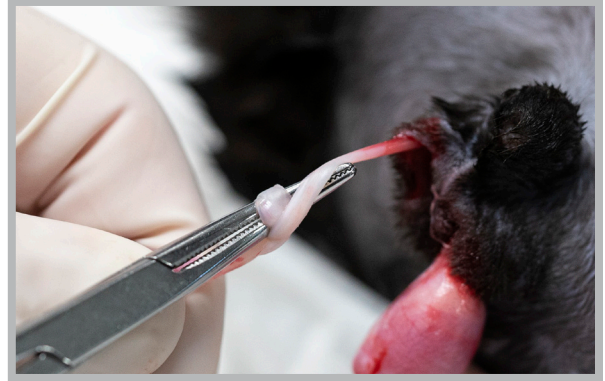
1. Place the hemostat on top of the cord.



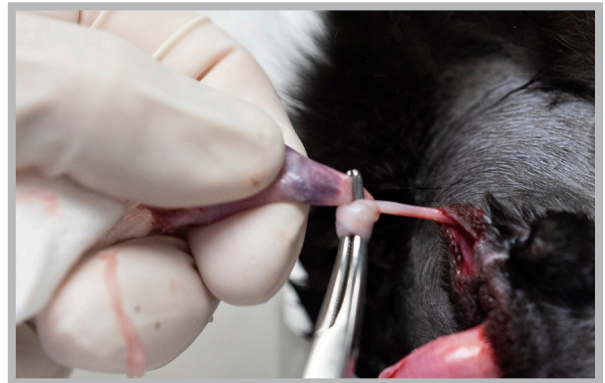
2. Wrap the distal (testicle) end of the cord over the hemostat once.



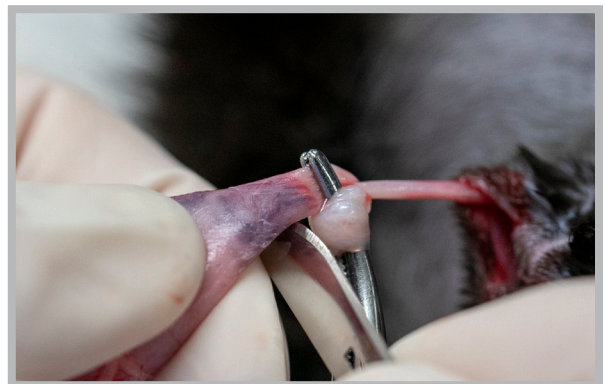

## Figure 8 Knot (cont.)



3. Direct the cord-wrapped hemostat ventral to the cord, passing it under and around.

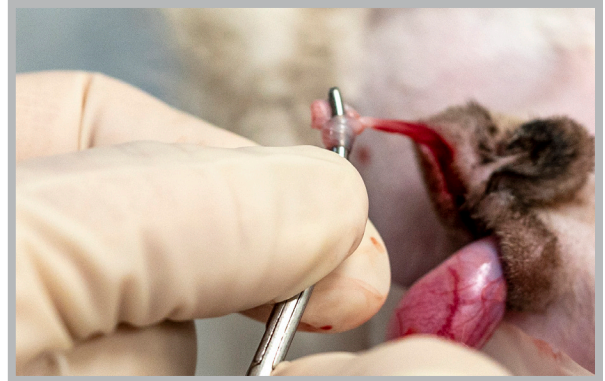


4. The jaws of the hemostat are then opened as the distal (testicle) end of the cord is advanced around and up into them and clamped.

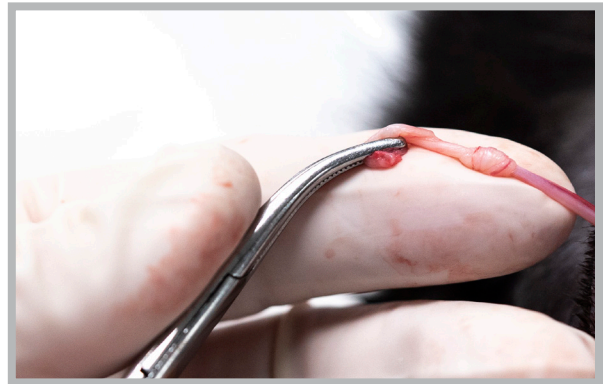


5. Next, the cord is divided between the clamp and testicle (close to the clamp) using a scalpel blade or scissors.

## Figure 8 Knot (cont.)



**6.** Following removal of the testicle, the surgeon pushes the knot off of the tip of the hemostats. The knot is tightened to ensure its security as the surgeon applies gentle proximal pressure to it.



**7.** If necessary, excess cord may be trimmed, but it is important to leave approximately 5 mm distal to the knot to ensure that it does not unravel. Inspect for bleeding before releasing.

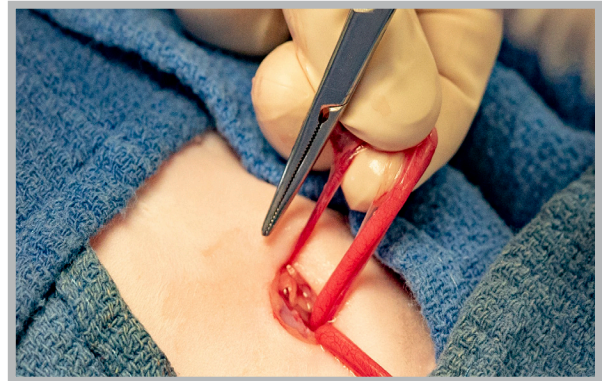



## Chapter 4: Ovarian Pedicle Tie (Cats Only)

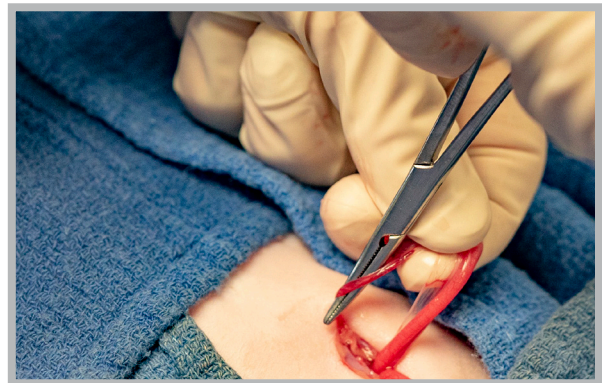
The ovarian pedicle tie is an autoligation technique performed with a mosquito hemostat on the ovarian pedicle in (only) felines. There are two ways to perform the technique. Both options are actually mirror images of one another and the method chosen is according to surgeon preference.

### Method 1

CLICK FOR MORE  
RESOURCES

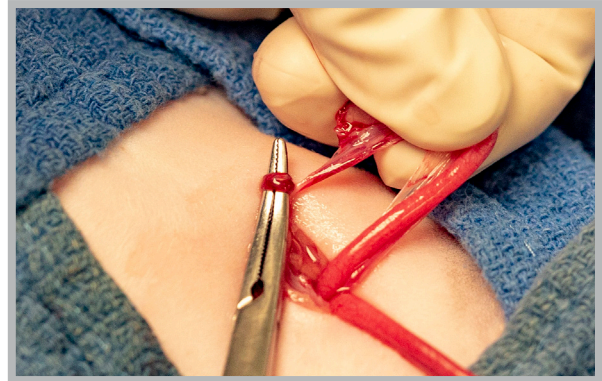

**1.** The ovary is retracted from the incision *away from* the surgeon, and the suspensory ligament and ovarian artery are identified. *Note: The suspensory ligament is transected as close to the ovarian pedicle as possible.* An aperture is created in the broad ligament adjacent to the ovary.

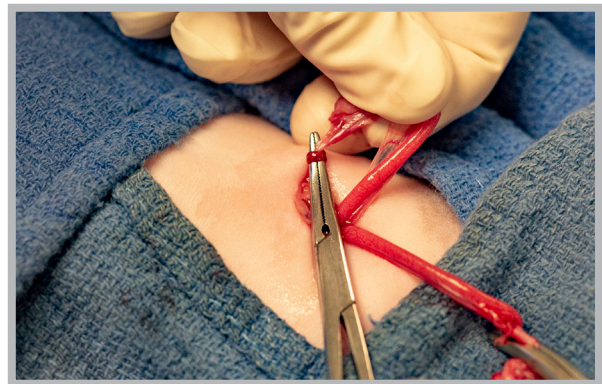


**2.** The pedicle is now isolated and ready for ligation. The hemostat is held in the closed position with the jaws pointing *toward* the surgeon; it is passed behind the pedicle and through the aperture in the broad ligament.

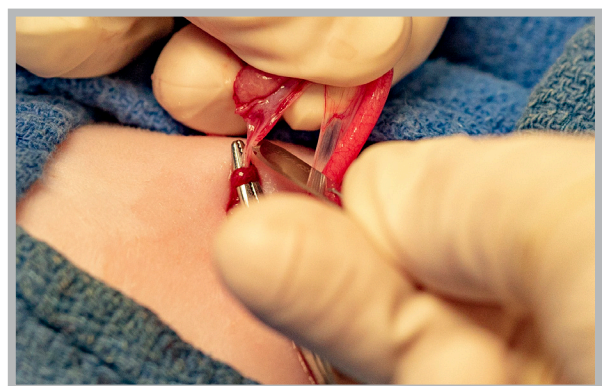

## Ovarian Pedicle Tie - Method 1 (cont.)



3. The tip of the hemostat is directed over the *near side* of the pedicle and the entire instrument is turned 180 degrees.

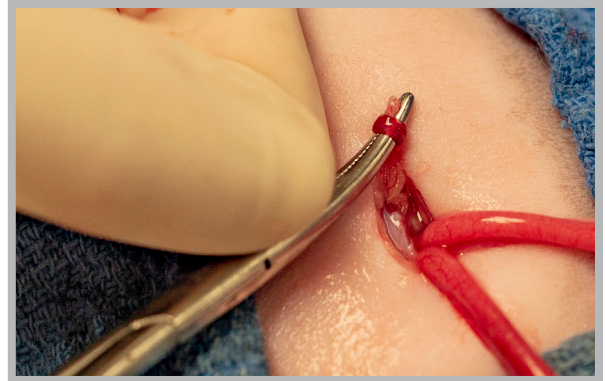


4. The pedicle is loosely clamped with the tips of the hemostats.

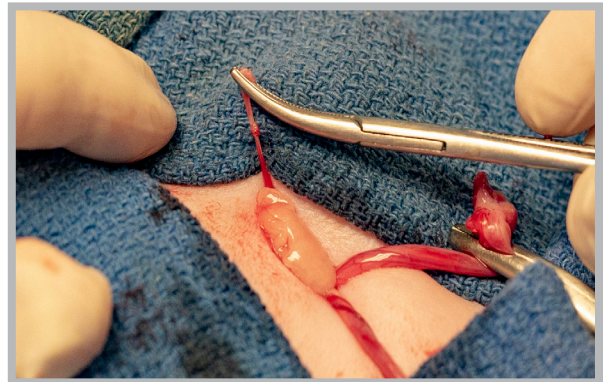



5. The pedicle is divided between the ovary and the hemostat, and the ovary and uterus are laid down to one side of the surgery field (Note: an additional hemostat is placed just proximal to the ovary to prevent bleeding following division from the pedicle).

## Ovarian Pedicle Tie - Method 1 (cont.)



6. The hemostat is clamped completely shut and the surgeon pushes the knot off the tip of the hemostat.

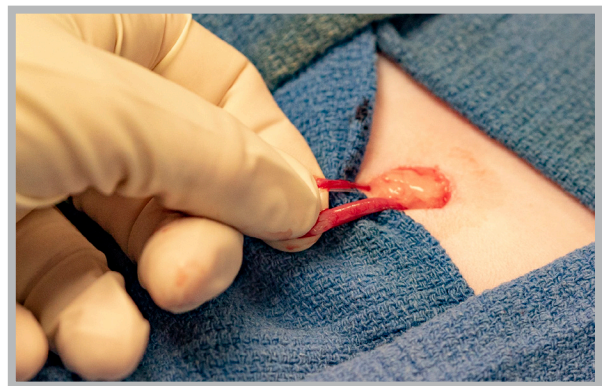


7. The knot is manually tightened and the pedicle inspected for hemorrhage.

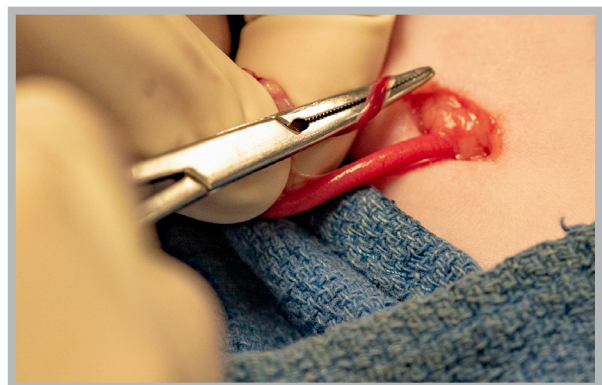

## Ovarian Pedicle Tie (Cats Only)

### Method 2

CLICK FOR MORE  
RESOURCES →

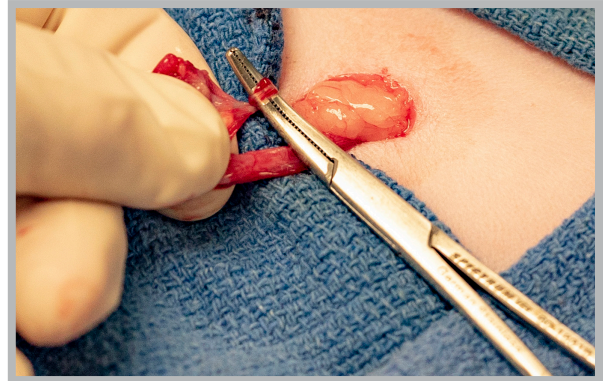



1. The ovary is retracted from the incision *toward* the surgeon, and the suspensory ligament and ovarian artery are identified. *Note: The suspensory ligament is transected as close to the ovarian pedicle as possible.* An aperture is created in the broad ligament adjacent to the ovary.

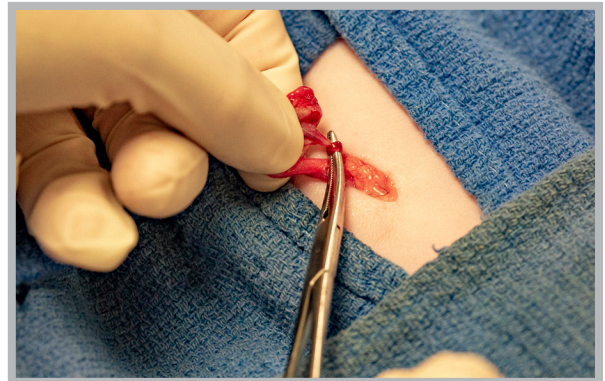


2. The pedicle is now isolated and ready for ligation. The hemostat is held in the closed position with the jaws pointing *away from* the surgeon; it is passed through the aperture in the broad ligament and behind the pedicle.

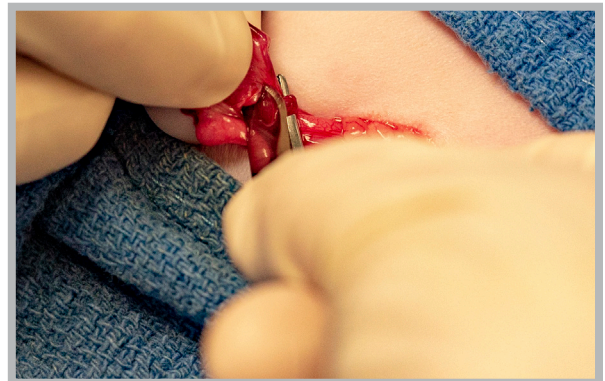
## Ovarian Pedicle Tie - Method 2 (cont.)



3. The tip of the hemostat is directed over the *far side* of the pedicle and the entire instrument is turned 180 degrees.

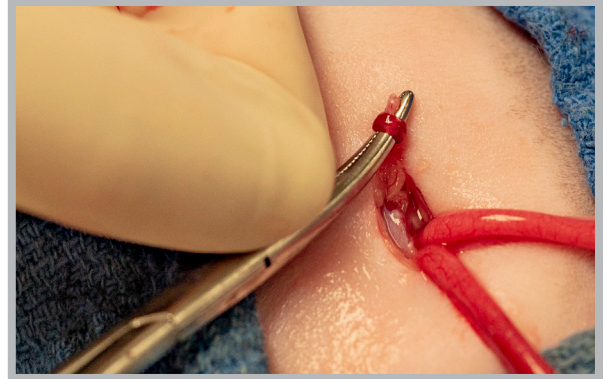


4. The pedicle is loosely clamped with the tips of the hemostats.

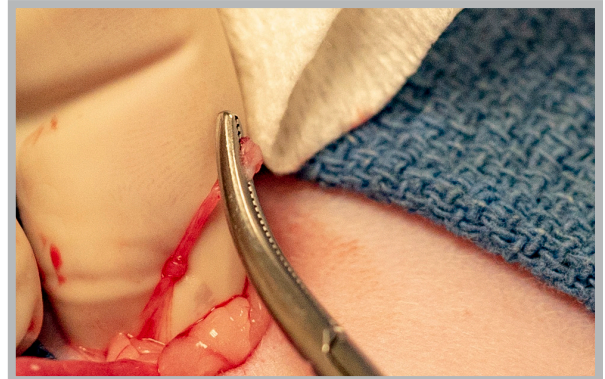


5. The pedicle is divided between the ovary and the hemostat, and the ovary and uterus are laid down to one side of the surgery field (Note: an additional hemostat is placed just proximal to the ovary to prevent bleeding following division from the pedicle).

## Ovarian Pedicle Tie - Method 2 (cont.)



6. The hemostat is clamped completely shut and the surgeon pushes the knot off the tip of the hemostat.



7. The knot is manually tightened and the pedicle inspected for hemorrhage.

## Chapter 5: Strangle Knot

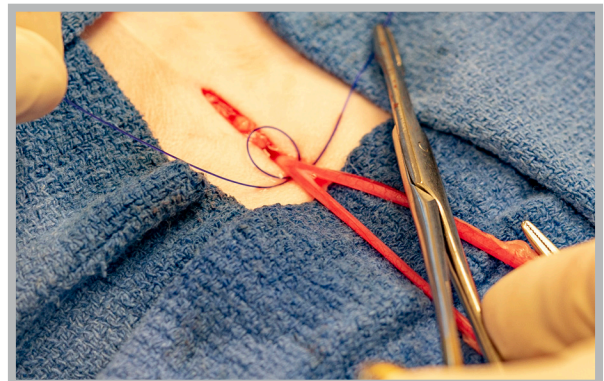**The strangle knot** is a binding knot of the friction knot category and as such is a very secure tie for ligatures. It is easily learned and rapid to perform as an instrument tie, enabling the surgeon to quickly apply a secure ligature to thick tissues such as the uterine body, eliminating the need for double ligation.

The strangle knot can be used to securely and efficiently ligate the uterine body, ovarian pedicle, or spermatic cord of dogs and may be particularly helpful when tissues are friable. This is because it distributes pressure over a greater surface area than a single encircling ligature, thereby reducing the tendency to cut or crush friable tissue. The strangle knot is not always necessary in pediatric patients where a simple ligation is adequate unless tissues are thick or well-developed.

Two options are demonstrated for setting up this knot (on-tissue and in-hand) and are chosen according to surgeon preference.

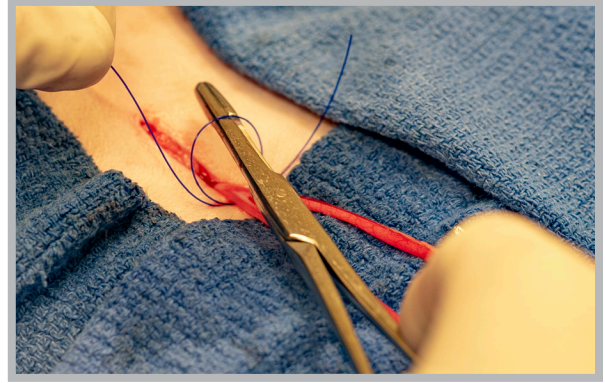

[CLICK FOR MORE RESOURCES](#) →

### Strangle Knot Method #1: On-Tissue Technique

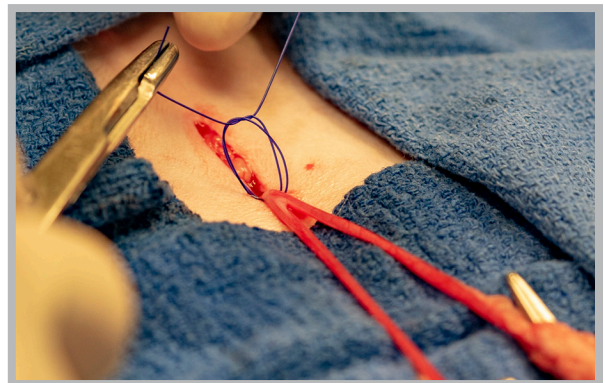



1. The strangle knot is created by passing a length of suture material around the tissue twice, creating a loop.

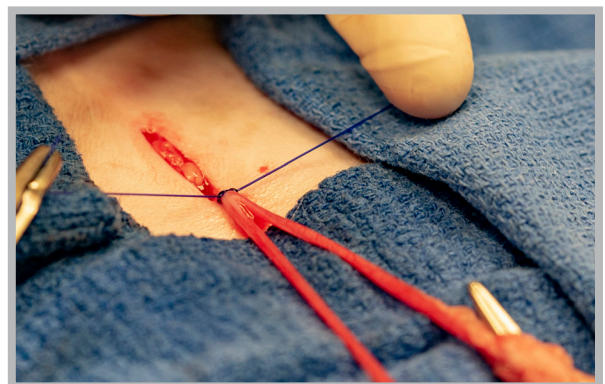

## Strangle Knot Method #1: On-Tissue Technique (cont)



2. The needle holders are then passed through the loop and the surgeon proceeds by creating a standard square knot throw.



3. The knot is secured, ensuring that both loops are tightened evenly (hint: elevating the loops as they are tightened is helpful). This will ensure that the tissue is thoroughly compressed.

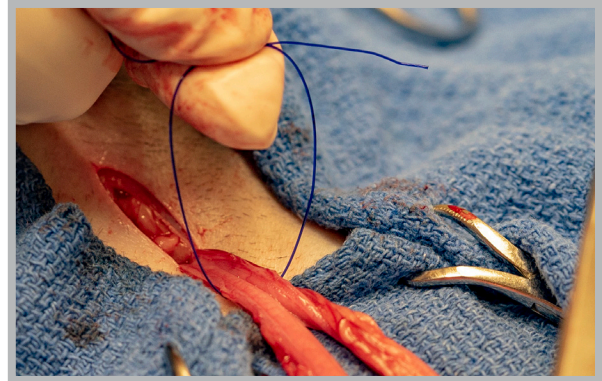



4. The strangle knot is then finished with a series of square knots to prevent loosening.

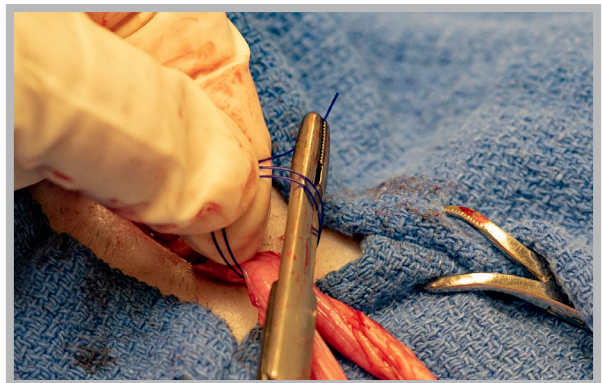
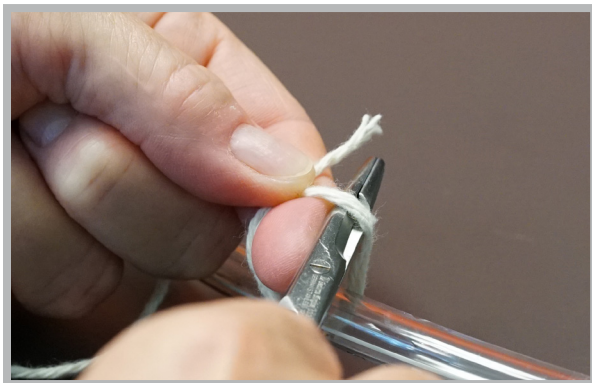


## Strangle Knot Method #2: In-Hand Technique

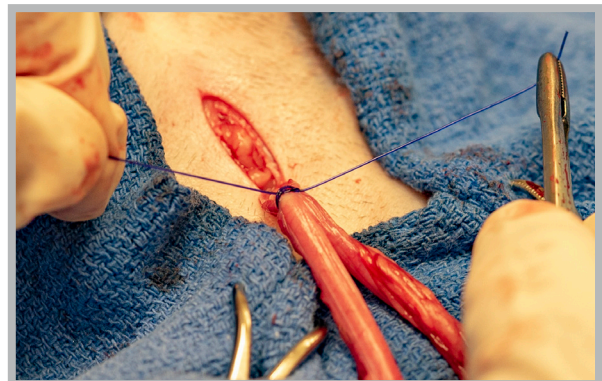

CLICK FOR MORE RESOURCES →



1. The strangle knot is created by passing a length of suture material around the tissue twice, creating a loop.



2. The needle holders are then passed through the loop and the surgeon proceeds by creating a standard square knot throw.



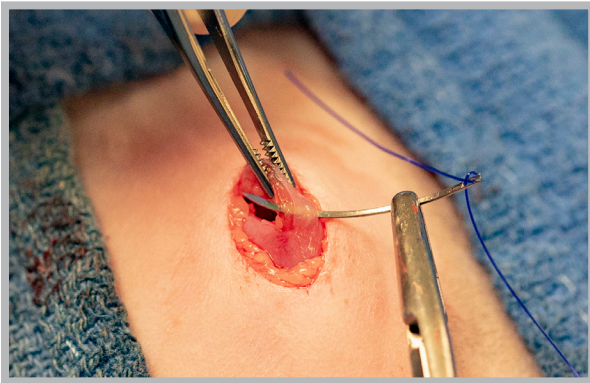
3. The knot is secured, ensuring that both loops are tightened evenly (hint: elevating the loops as they are tightened is helpful). This will ensure that the tissue is thoroughly compressed. The strangle knot is then finished with a series of square knots to prevent loosening.

## Chapter 6: Closure of the Rectus Sheath

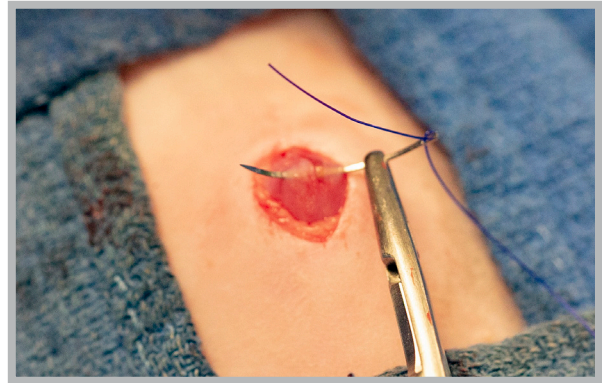
CLICK FOR MORE  
 RESOURCES →

**A secure body wall** is crucial to protect against dehiscence. Ideally, gentle tissue handling with appropriately placed bites in the rectus sheath are ensured with attention to proper knot-tying technique (good snug square knots).

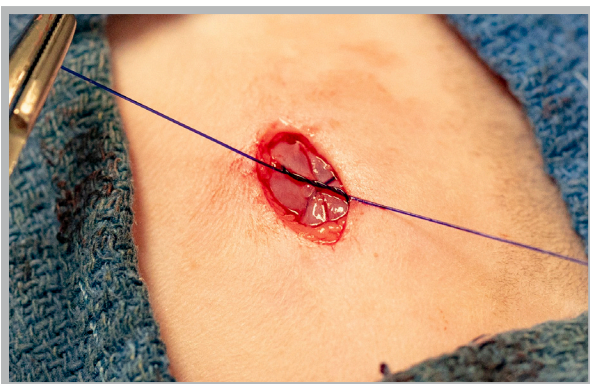- Attention to proper knot-tying technique (good snug square knots).
- Gentle tissue handling.
- General guidelines for bite size include:
  - Large Dogs: 1.0 cm
  - Cats, Puppies and Small Dogs: 0.5 cm




**1.** The goal is to take the holding layer (rectus sheath), avoiding the muscle.



**2.** Adequate and equal bites on each side are imperative.



**3.** The most important feature of closure is to avoid crushing necrosis of the body wall/rectus.



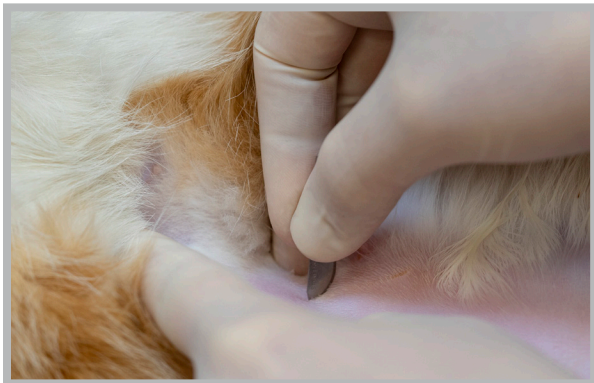**4.** Avoidance is best accomplished by a combination of an appropriately 4:1 ratio and by not pulling on the suture too tightly.

## Chapter 7: Scoring Tattoo

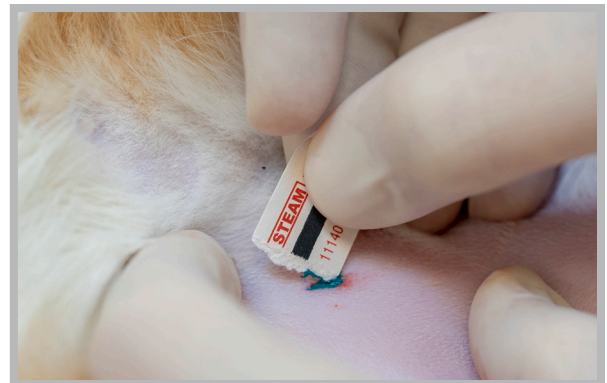CLICK FOR MORE  
RESOURCES →

**Tattoos are used as an indicator that an animal has been spayed or neutered.** This is sometimes called a scoring tattoo, since the skin is scored with a scalpel blade, and paste is then applied. It is a simple, cost-effective method to ensure the animal never has an unnecessary future exploratory to determine reproductive status. This closure technique prevents patients from licking the tattoo and developing a temporary case of “green tongue” in recovery.

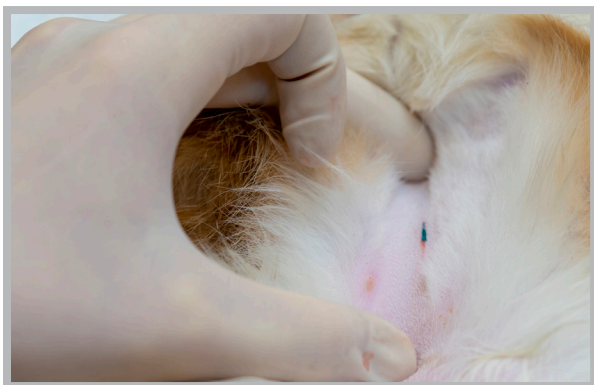- Both female dogs and cats should have the tattoo placed near the incision site.
- Male dogs should have the tattoo placed in the pre-scrotal area.
- Male cats should have the tattoo placed where an incision would be searched for in a female cat (as neutered male cats are often misjudged as females).



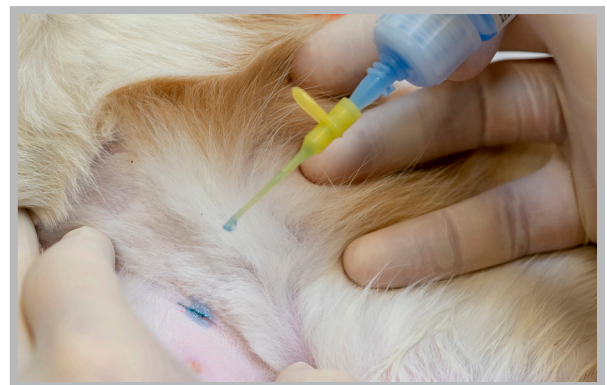1. The skin is scored with a scalpel blade.



2. Paste is applied to the scored tissue.



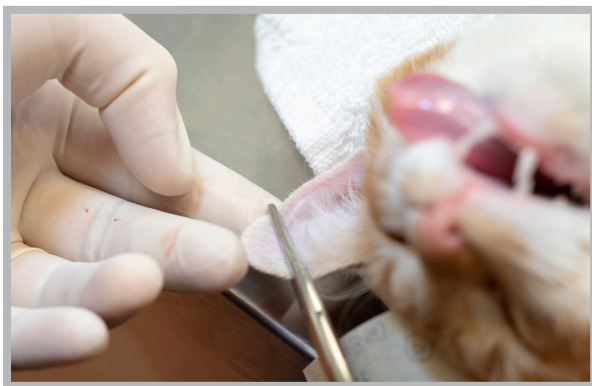
3. The skin edges are slightly inverted



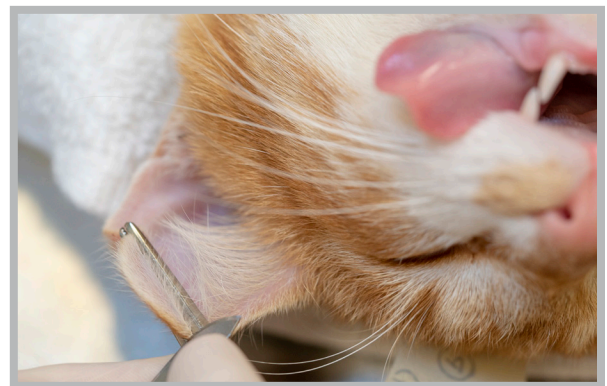
4. A drop of tissue adhesive is applied on top of the skin for closure.

## Chapter 8: Ear-tipping

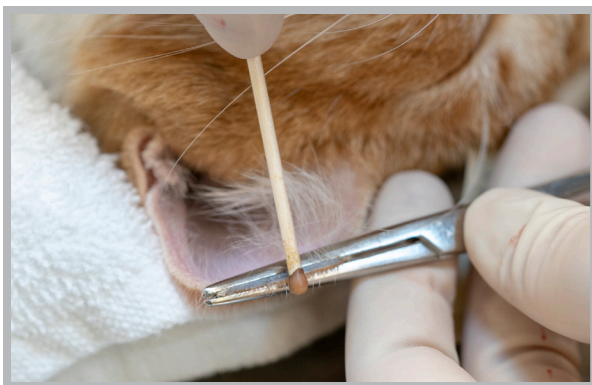
**Removing the tip of the ear** in community cats is a universal sign permanently identifying the cat as having been spayed or neutered.




**1.** A straight hemostat is placed perpendicular to the long axis of the pinna, exposing proportionately approximately 1/3 of the tip of the ear.



**2.** The tip of the ear is removed *using the straight scissors* or scalpel blade to cut over the edge of the hemostats.



**3.** The hemostats are left in place until hemostasis occurs. A silver nitrate stick can encourage hemostasis.



**4.** Proper appearance of an ear after being cropped. Note the distinctive straight edge that is easily recognizable from a distance.